

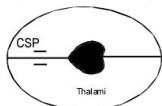
Fetal Anatomy:

Normal= N

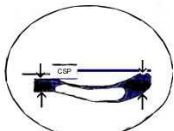
Abnormal = AbN

Skull and Brain:

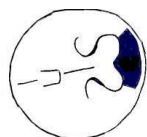BPD Plane



Ventricular Plane



TCD Plane



Face:

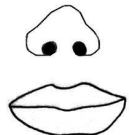
Facial Profile



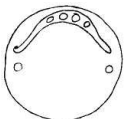Eyes Transverse



Lips Coronal

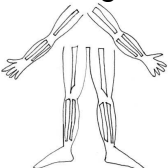


Palate Transverse



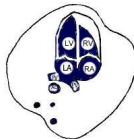
Limbs:

12 Longbones



Chest:

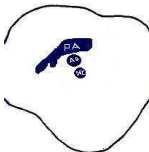Heart 4Ch View



Outflow tracts

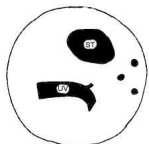


3 Vessel View



Abdomen:

AC View



Stomach

Visible/ Not

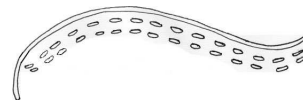


Abd Wall

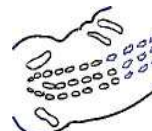

Spine:

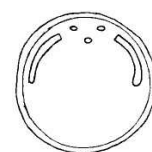
Longitudinal



Coronal

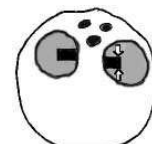

Transverse



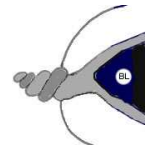
Urogenital:

Kidneys x 2



Bladder

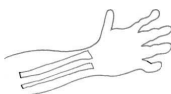Visible/ Not



Fetal Sex:

Male Female

2 Hands



2 Feet



